

Minimally Invasive Wrinkle Release

Release deep lines and scars in seconds

SurgiWire™
Incisionless Dissector



MICROAIRE®
aesthetics

How to perform the SurgiWire Wrinkle Release procedure

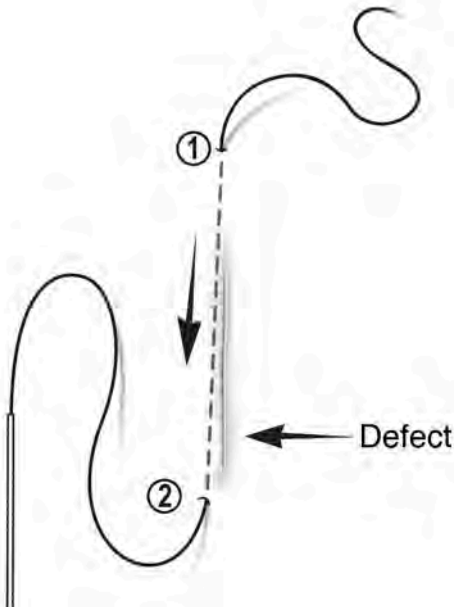


Figure 1: Insert the needle at the top of the defect (1) and closely follow the line of the defect. The needle should emerge at the bottom of the defect (2).

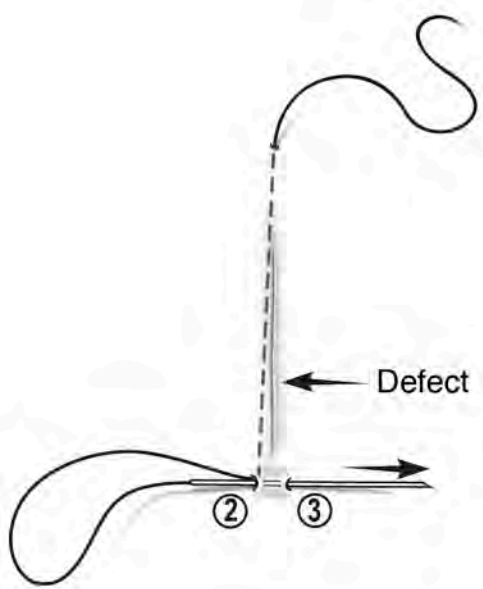


Figure 2: Reinsert the needle (2) into the hole at the bottom of the defect and bring the needle out along the bottom of the defect (3).

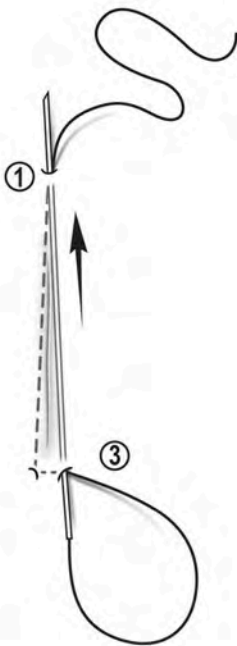


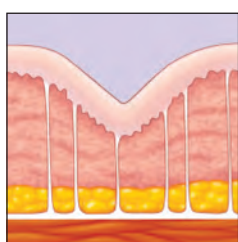
Figure 3: Reinsert the needle at the previous puncture site (3). The final exit point is the first puncture (1).



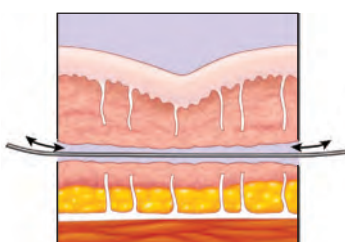
Figure 4: Cross the wire strands, and dissect the tissue with a smooth back and forth motion.

SurgiWire is an instrument that releases wrinkles from underlying tissues

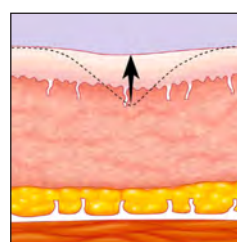
It consists of two Keith needles joined by a three foot section of fine gauge surgical grade steel twisted using a proprietary technique.



PRE - TREATMENT



SURGIWIRE RELEASE

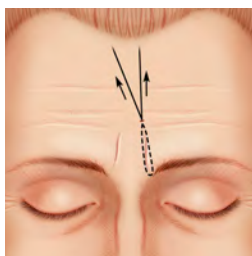


POST - TREATMENT

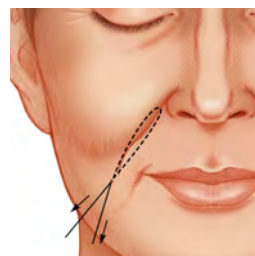Now there's a device and minimally invasive procedure for patients with deep skin defects like glabellar creases, nasolabial folds, and scars. With just a few skin punctures, the ingenious SurgiWire completely releases Grade IV and V lines, folds, scars, and depressions. Simple, direct, and minimally invasive, the SurgiWire incisionless dissector offers patients new options with proven results and satisfaction. Expand your filler practice by treating patients with severe wrinkles on whom fillers alone are no longer effective.

Applications

Examples of the most commonly performed SurgiWire Wrinkle Release procedures



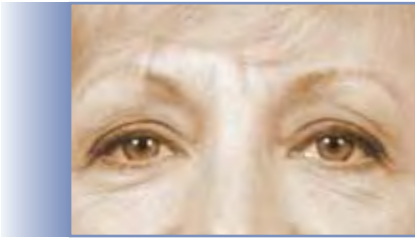Glabellar Line Release



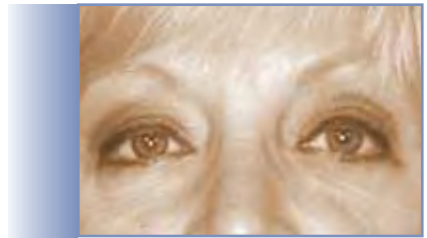Nasolabial Fold Release

Results of SurgiWire Wrinkle Release Procedures

Glabellar Release in 61 year old female



BEFORE

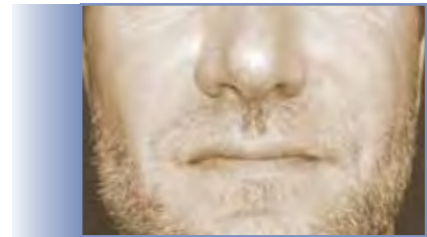

AFTER 16 MONTHS
No Filler

Nasolabial Fold Release in 42 year old male

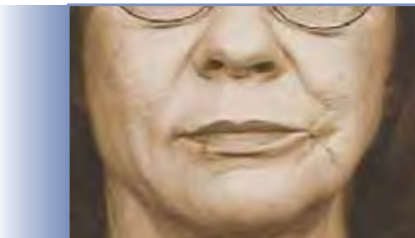

BEFORE

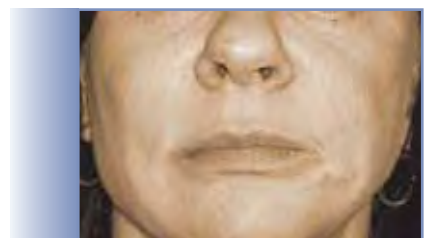

AFTER 16 MONTHS
No Filler

Nasolabial Fold and Macroscopic Scar Release in 40 year old female

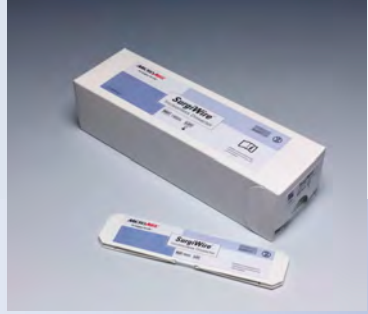


BEFORE



AFTER 16 MONTHS
Fat Injection Immediately
Post Procedure

Fast • Versatile • Outstanding Results



Key Benefits

- ✓ Reduce Grade IV or V wrinkles to Grade I or II with no incisions or scars
- ✓ Fast procedure, fast recovery under local anesthesia
- ✓ Can be used with or without fillers or laser resurfacing
- ✓ Nothing left behind in the body
- ✓ Attractive results within a few days of the procedure
- ✓ Generate immediate practice revenue for a minimal time investment

The SurgiWire Incisionless Dissector . . .

*. . . an essential innovation for
aesthetic practitioners.*

Wire Subcision for Complete Release of Depressions, Subdermal Attachments, and Scars

Miles Graivier, M.D.

Background: Deep lines, facial folds, retracted scars, and contour depressions on all areas of the body have typically been resistant to efforts at release.

Objective: A method using a wire dissector to achieve complete release or subcision of these subdermal attachments with access only through the needle insertion sites is described.

Methods: The wire dissector was inserted into the subcutaneous tissue just below the dermal-subcutaneous tissue junction and brought out of the skin on one side of the defect. The needle was then passed back and forth through the same puncture holes until the depression was circled entirely in the subcutaneous plane by the wire. Traction was applied by the assistant, and the wire was sawed gently back and forth until the depression was completely released.

Results: The areas most commonly treated with the wire were the deep nasolabial folds; among the other areas treated were marionette lines, cheek and chin lines, and retracted scars of the face and body. Of 38 patients treated, 27 underwent simultaneous fat injection, 1 received an AlloDerm (LifeCell Corp., Branchburg, NJ) graft, 1 received a Radiesse (Bioform Medical, Inc., San Mateo, CA) injection; and 1 received injection with Sculptra (Dermik Laboratories, Berwyn, PA). Eight patients had nothing placed under the subcision area. Follow-up of 1 to 19 months showed persistent correction in all patients. Postoperative complications included one hematoma, one localized abscess, and overcorrection in three cases where fat was used.

Conclusions: The wire dissector holds promise as a tool for complete subcision of deep lines, folds, depressions, and scars of the face and body without incisions and with few complications.

(*Aesthetic Surg J* 2006; 26: 387-394.)



MicroAire Surgical Instruments
1641 Edlich Drive
Charlottesville, VA 22911
800.722.0822
+434.975.8000
www.Endotone.com